



Histoanatomical Study of Tongue in Maku strain mature goat

Ramin Jahangirfard*, Gholamreza Najafi**, Seyed Rashid Touni***, Mohammad Divan****
and Sepideh Tavallae*****

*Ph.D. student of Anatomy and Embryology, College of Veterinary Medicine, Urmia Branch, Urmia, Iran

**Department of Anatomy, College of Veterinary Medicine, Urmia Branch, Urmia, Iran

***Young Researcher and Elite, Urmia Branch, Islamic Azad University, Urmia, Iran

****Veterinary Students, College of Veterinary Medicine, Urmia Branch, Urmia, Iran

(Corresponding author: Ramin Jahangirfard)

(Received 12 August, 2015, Accepted 09 October, 2015)

(Published by Research Trend, Website: www.researchtrend.net)

ABSTRACT: Macroscopic and microscopic evaluation of Maku breeds goat's tongue tissue. Twelve adult male and female goats were selected and their tongue was studied. The samples were stained by Hematoxylin and Eosin method. Macroscopic findings essentially were the same as the other goats but male Maku breed goat has a snow-white tongue, and the female's tongue is darker that probably due to a lot of melanin pigments. In microscopic findings the cup-shaped papillae was along with taste groove and serous-glands. Filiform, mushroom-shaped, cone-shaped, and lens-shaped microscopy were observed using optical microscope.

The foliate papillae were not seen and almost a tick cuticle-layer around the papillae was observed. It must be noted that the intraepithelial taste buds were observed on top of mushroom-shaped papillae and on the side surface of the goblet papillae. The tongue is similar in both sexes in terms of size and structure.

Keywords: Goat, lingual papillae, H & E staining

INTRODUCTION

Goat with the scientific name *Capra Aegagrus hircus* is a domestic animal of the order of Artiodactyla, the family of Bovidae, the subfamily Caprinae and the genus of *Capra* that becomes mature sexually after one year-old. In the world there are more than 200 breeds of goat and 10 of which are very important in terms of productivity (milk, meat and wool). Maku-breed goats have black wool, but other colors have also been seen. Its products include cashmere and milk and its breeding place is West Azerbaijan (Khaldari, 2005). Tongue is the moving muscle that is covered by mucus and it is kept by the hyoid bone at the back side and by mandible in front and lower side. Some actions such as Reception, Mastication, and Deglutition are fulfilled by the tongue (Ebrahimi-saadatlou, 2011). Tongue has three parts: root, body, and apex, as well as two surfaces: Dorsal and Ventral surfaces. Lingual root attaches to the Soft palate by Frenulum linguae (Dyce, *et al.*, 2009). It should be noted that the root is a part of the tongue that lingual process of hyoid bone is located. Ruminants have a prominent ridge on the dorsal surface of tongue that is called Torus Linguae; also there is a dent in the front of tongue that is called Lingual fossa. In the horse, on the tongue midline and close to its dorsal surface a cartilage is seen which is called dorsal lingual cartilage. The free part of tongue in dogs has a greater mobility. There is a deep groove at the dorsal part of dogs' tongue which is called median groove (Getty, 1975). Another feature of the carnivores' tongue

is a structure called Lyssa which is seen in the cross-section of linguae free part and located near the ventral part of the tongue that contains connective tissue, white fat tissue and skeletal muscle is surrounded by a capsule of dense and irregular connective tissue. Lingua epithelium is of horny stratified squamous in the dorsal part, but on the ventral surface it is non horny. Dorsal surface of the tongue has Mechanical papillae (filiform, conical shape and lenticular) and gustatory papillae (fungiform, goblet-shaped and foliate Papillae). Filiform papillae are the most frequent type of papillae. The papillae are small in dogs. In the horse and ruminants it is located at the dorsal surface of the tongue and in ruminants they are located a head of Torus Linguae. They are drawn also to the lower tip of the tongue. Conical Papillae are located in the root of the tongue which is seen also on the lips and cheeks in ruminants. Lenticular Papillae can be found on the torus linguae of the ruminants. Fungiform Papillae are scattered among filiform papillae as well as lateral sides of the tongue tip. The papillae are dome-shaped in horse. Circumvallate Papillae have been located in the anterior root of the tongue and are surrounded by a groove of the epithelium, and a group of Ebner glands are presented the depth of the groove (Eurell and Frappier 2013). Their number varies in different animals (8-17 in cattle, 18-24 in sheep, 12-18 in goats, and 2 in horses). Foliate Papillae are as atrophied bodies on the edge of cattle tongue. These papillae are seen as a series of parallel grooves on the horse tongue.

They exist on the rabbits tongue. There are some glands on the tongue called Lingual glands that are located along the side edge of the lower surface of the tongue; also there are others glands called ebner, weber, and ebnero weber on the tongue root which secrete ebner and weber.

According to the conducted studies and because of the physiological importance of tongue and its morphological differences between different breeds, the Maku goat's tongue was selected to study, because it has not been studied so far. Its anatomy and histology were studied in adult male and female sexes.

MATERIALS AND METHODS

In this study, 12 adult Maku breed goats (6 males and 6 females) with an average age of between 1 and 2 years old were obtained from West Azerbaijan laughter houses. The animals were dissected, and then animals' heads were washed and placed on the trays to transfer to the autopsy hall in order to anatomical studies. After removing the skin, facial muscles pulled aside and then lower jaw and upper jaw were separated from each other from the binding region. The preliminary studies were conducted on both sexes, including the color of the tongue, the way of connection the tongue to the hyoid bone and soft palate. In the next step, morphological measurements such as length, width and height of the lingual root, body and tip were measured by caliper. Then measurement so fall three sections of elementary, middle and end of tongue were done. Measures of Torus Linguae and Lingual Fossa were performed. In order to histological and anatomical study, 1 × 1 Cm of different parts of the root, tip, and body of the tongues of 3 male and 3 female were sampled and then were fixed in 15% formalin solution. Following the fixation, the samples were placed in histotechnic device. After molding with paraffin, some sections with the thickness of 5µ were prepared and stained with Hematoxylin and Eosin and subsequently studied by optical microscope. Data analysis (comparing the length, width and height of each of the three parts of the tongues of the both sexes) were performed using SPSS version 22. T-test was used to

determine the significance of difference between data (p<0.05).

RESULTS AND DISCUSSION

A) Lingual Anatomy

The tongue in Maku goat is quite similar to other ruminants. The visible differences between the tongues of the two sexes are the color, torus linguae, and lingual fossa. Torus linguae had great shape at the root of the tongue and the fossa linguae in females were little deeper than males. Tongue color in male goat was now-white and in female it was darker in the body and tip of the tongue which was extended to the torus linguae. Lingual papillae were similar in terms of distribution and form, in both sexes. Filiform papillae, in both sexes, were located similarly in the back and front of the torus linguae. Filiform papillae, like sheep were extended to the lower part of tongue tip. Two conical and lenticular papillae were located on the surface of the torus linguae. Fungiform papillae were observed along the lateral edges of the tongue. The circumvallate papillae were observed behind the torus linguae. Foliate papillae were not observed in Maku goats.

B) Measurement and statistical analysis

T-test results showed no significant difference between the length, width and height of the different tongue parts of both sexes. The mean and standard deviation (SD) of length and width of each part are shown in Table 1.

C) Histology

The prepared tissue samples were kept into 15%formalin solution for 15 days in histology laboratory of Orumieh University. A thickness of 5µ was cut from each sample after molding with paraffin. The samples were processed and stained by H&E method. In microscopic study the Filiform papillae are the most abundant type. They are rod-shaped and thread-like structures of the language that is highlighted by stratified squamous epithelium and are covered by an almost thick horny layer. The connective part of these papillae has several secondary papillae. The conical papillae are located on the torus linguae of Maku goats.

Table 1: The mean of length, width, and height of tongue (mm).

	Male		female	
	Mean	SD	mean	SD
Tongue length	16.4	2.08	15.2	1.69
Apex width	2.83	0.39	2.21	0.34
Body Width	3.19	0.53	2.64	0.41
Root width	1.71	0.29	1.39	0.21
Torus linguae length	7.56	0.96	6.22	0.81
Torus linguae width	3.52	0.74	3.24	0.61
Torus linguae height	2.51	0.40	2.13	0.27
Apex height	0.4	0.07	0.31	0.05
Body height	0.83	0.16	0.69	0.11
Root height	0.61	0.09	0.48	0.06

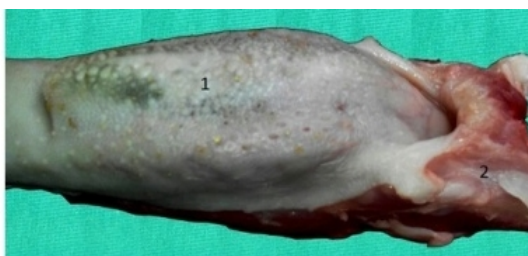

Fig. 1. Macroscopic view of lingual papillae (1) and hyoid apparatus connected to the tongue root.

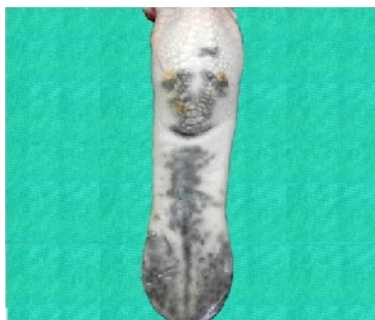


Fig. 2. Macroscopic view of the female goat. Note: it is in dark col.

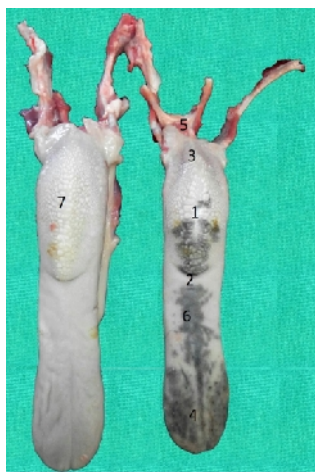

Fig. 3. Macroscopic view of linguae torus (1), lingual fossa (2), tongue root (3), tongue tip (4), hyoid apparatus, tongue body (6), lingual papillae. Female tongue (right side), Male tongue (left side).

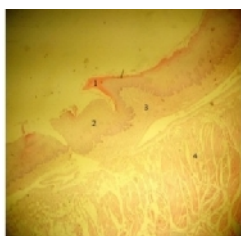


Fig. 4. Microscopic view of Filiform papillae horny layer (1), epithelium (2), connective tissue of the papillae nuclear (3), lingual muscles (4). (Magnification X10).

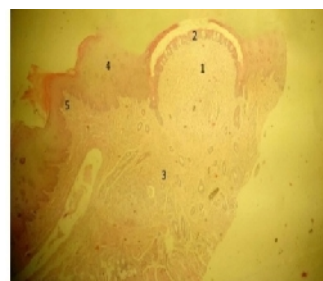


Fig. 5. Microscopic view of fungiform papillae (1), Taste buds of intraepithelial (2), connective tissue (3), epithelium (4), Filiform papillae (5). (Magnification X10).

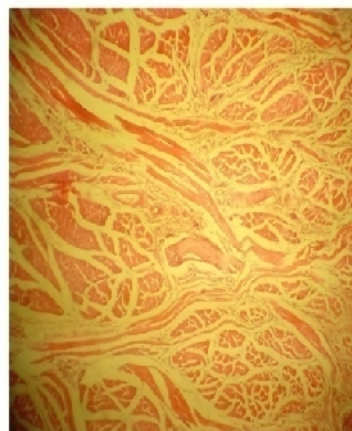


Fig. 6. Microscopic view of lingual muscle. (Magnification X10).

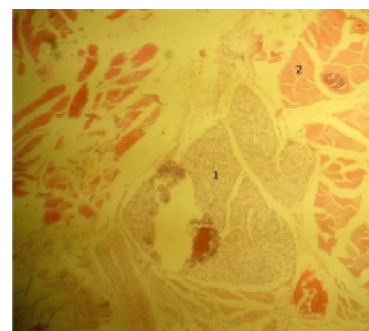


Fig. 7. Microscopic view of the ebner (1) and lingual muscles (2). (Magnification X10).

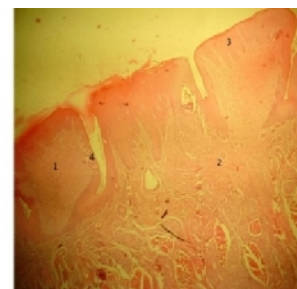


Fig. 8. Microscopic view of the circumvallate papillae (1), connective tissue (2), epithelial tissue (3) and gustatory buds (4). (Magnification X10).

They are larger than the pores. They are larger than Filiform papillae and not a lot horny. In ruminants, these papillae contain both primary and secondary papillae. Lenticular papillae are flat papillae that are found on the torus lingua of ruminants. These papillae are covered by horny stratified squamous epithelium and have adense irregular connective tissue in nuclear. Fungiform papillae are scattered among the Filiform papillae and they are like mushrooms they are called fungiform papillae. The upper surface of them of them has been covered by non-horny stratified squamous epithelium containing several taste buds. Taste buds number of fungiform papillae is small in cattle, is more in sheep and much more in goats. Also the connective nuclear of these papillae is rich of blood vessels and nerves. Circumvallate papillae are located in dorsal surface just in front of the origin of the tongue. They are big and wide structures and completely surrounded by a groove which is covered by epithelium. These papillae are prominent slightly in dorsal surface of the tongue or they are not prominent at all and they are covered by a stratified squamous epithelium. The epithelium of papillae has many taste buds in front of the groove. Gustatory glands groups are located in the deep of the groove and their channel opens at different levels into the groove. Weber may be found under the papillae but their excretory duct opens to the tongue surface directly. The numbers of these papillae in ruminants are 8 to 24 pairs. It must be noted that the ruminants have no foliate papillae. Also, histology of tongue is similar between the two sexes. The studies of Funa to *et al.*, in 1985 on East Asian antelope (Formosan Serow) showed that tongue structures are similar but significant differences compared with Formos an breed were observed (Funato *et al.*, 1985). Differences in size, color, tip of the tongue, the number of filiform, fungiform, and lenticular papillae were observed. The lingual length in Formos an breed is less than 1cm and the edge of the tongue tip is U-shaped, but in Maku the tongue length is more compared with Formosan goat. The edge of tongue tip is similar in both of which. The difference in tongue tip exists with Japanes Serow. In Japanes Serow the tongue tip is V-shaped. It should be noted that the tongue tip of Saigais U-shaped (Frey and Hofmann 1995). The tongue color is dark in female goat, but it is white in male goat that is one of the significant differences compared with the other goats. Filiform and fungiform papillae are almost similar in Formosa and Maku goats, but their size is shorter than Japanese breed papillae. The Secondary papillae were observed on the base of the Filiform

papillae in both of the breeds. Some of the Circumvallate papillae were found quite similar to the Japanese breed papillae, but the size of Circumvallate papillae is diverse in Formosa goats while the Maku goats have unified papillae. Lenticular papillae were not observed on dorsal surface of Formosa goats but they were not seen in Maku and Japanese breed. Fungiform papillae have no taste buds in dorsal part of the Formosa goat tongue (Qayyum and Beg, 1975) but they were seen in Maku and Japanese goats' tongue. In this study the spread of tongue papillae is almost similar to the Japanese breed goats. It can be concluded that the color of the tongue is snow-white in males, but it is darker in females which is may be because of melanin pigment. Also, the size of the tongue depends on the age, breed and size of the animal's head that it will be longer if the head is larger and vice versa. In microscopic view, an almost thick cuticle is found around the Filiform papillae. Ebners were found as lobulation observed. In this study no foliate papillae was seen.

REFERENCES

- Khaldari, M. (2005). Principle of sheep and goat husbandry Jahad university publication. jahad university publication, p.114-126.
- Ebrahimi-saadatlou, M.A. (2011). Basic of veterinary Anatomy. Sotodeh publication; Iran. Sotodeh publication, Iran, p.144-149.
- Dyce, K.M., Sack, W.O., Wensing, C.J.G. (2009). Textbook of veterinary anatomy. Elsevier Health Sciences. Elsevier Health Sciences.
- Getty, R. (1975). Sisson and Grossman's The anatomy of the domestic animals. W.B. Saunders company; Philadelphia, London, Sisson and Grossman's. The anatomy of the domestic animals. (W.B. Saunders company, Philadelphia, London, p.865-866.
- Eurell, J.A., Frappier, B.L. (2013). Dellmann's textbook of veterinary histology. John Wiley & Sons. John Wiley & Sons.
- Funato, H., Atoji, Y., Suzuki, Y., Sugimura, M. (1985). Morphological studies on the tongue of wild Japanese serows, *Capricornis crispus*. Research Bulletin of the Faculty of Agriculture-Gifu University (Japan).
- Frey, R., Hofmann, R. (1995). Der Kopf der Saiga-Antilope (*Saiga tatarica tatarica* Linnaeus 1766, Mammalia: Bovidae)-Ausgewählte funktionsmorphologische Aspekte. I. Die Speicheldrüsen, die Mandibula und die Zunge. *Zool Beitr* (NF). **36**: 169-98.
- Qayyum, M., Beg, M. (1975). Anatomical and neurohistological observations on the tongue of the Indian goat, *Capra aegagrus*. *Cells Tissues Organs*. **93**(4): 554-67.