

Occurrence and Pathology of Visceral Gout in Chickens

Udaya Sai Sitaram Tella^{1*}, Mridusmrita Buragohain², Abhijit Deka²,
Sravan Kumar Reddy¹ and M. Sai Kumar Reddy¹

¹M.V.Sc. Scholar, Department of Veterinary Pathology,
College of Veterinary Science, Khanapara, AAU, Jorhat (Assam), India.

²Assistant Professor, Department of Veterinary Pathology,
College of Veterinary Science, Khanapara, AAU, Jorhat (Assam), India.

(Corresponding author: Udaya Sai Sitaram Tella*)

(Received: 11 July 2023; Revised: 19 August 2023; Accepted: 20 September 2023; Published: 15 October 2023)

(Published by Research Trend)

ABSTRACT: The present study deals with the occurrence and pathology of Visceral gout in chickens. During 2021 and 2022, an incidence of visceral gout was recorded in the month of July and August in the carcasses brought to the Department of Pathology, CVSc, AAU, Khanapara. The mortality was 2.1% (i.e., 16) considering only among the month of July (i.e., 6), August (i.e., 10) and were diagnosed as Visceral gout. The effect of different breed and month on the occurrence of Visceral gout were studied. Mostly observed gross lesions include white chalky material on epicardial surface of heart and serosal surface of liver, spleen, lung and enlargement of kidneys with necrotic foci were found. On histopathological special staining with De Galantha revealed presence of urates crystals with black colour were recorded.

Keywords: De Galantha, Visceral gout, urates crystals, breed, month.

INTRODUCTION

Gout is one of the most common diseases in poultry, with the kidney being the primary organ involved (Ali *et al.*, 2018). Gout is a metabolic disorder that results of severe renal dysfunction that causes hyperuricemia in which crystals of uric acids or urates of sodium and calcium are deposited in the tissues (Mudasir *et al.*, 2017). It occurs as two distinct forms (a) Visceral gout if the urates are deposited in the kidneys and on serosal surfaces of heart, liver, mesentery or air sacs and (b) Articular gout if the urates are deposited around the joints of limbs (Lakshmi *et al.*, 2019). It is one of the most commonly diagnosed causes of mortality in poultry with symptoms like weakness, emaciation, difficulty in movement, restlessness, dehydration, ruffled feathers and blood uric acid levels can reach 44 mg/100ml, compared to 5-7mg/100ml in a healthy bird (Sandhyarani *et al.*, 2021).

Gout is not an only one disease entity, but rather the result of renal disease caused by a variety of factors, which can be infectious, nutritional, toxic, or a combination of factors (Sandhyarani *et al.*, 2021). The nutritional or metabolic causes of gout include Vitamin A deficiency, high levels of vitamin D3, high protein diet, dehydration due to water deprivation, inclusion of high calcium in broiler and layer diets. Other causes of gout include feed contaminated with mycotoxins such as oosporein, ochratoxin, treatment with Sodium bicarbonate and infectious causes of gout includes Avian Nephritis Virus (ANV), Infectious Bronchitis Virus (IBV) (Bulbule *et al.*, 2014).

MATERIALS AND METHODS

In the present study, the outbreaks of visceral gout in commercial layer flock of Daothigir, Dahlem red and kamarupa breeds presented for the post-mortem examination to the department of veterinary pathology college of veterinary science, A.A.U., khanapara. Age wise, breed wise mortality and gross changes were recorded and detailed post mortem examination were performed in died chickens. The affected tissues were collected in 10% neutral buffered formalin for histopathological examination (H & E) as per procedure of Luna (1968). Duplicate section of tissue was used for special staining technique DeGalantha's to demonstrate urates crystals in tissue (De Galantha, 1935).

RESULT

During the study, the mortality of 2.1% due to gout was recorded in the month of July and August, 2022 in flock of Daothigir (with 0.35%), Dahlem red (with 0.7%) and kamarupa breeds (with 1.05%) which were maintained under intensive system. Clinical signs reported were decreased feed, weakness, emaciation, difficulty in movement, restlessness, ruffled feathers, weight loss and abnormal droppings. On gross examination, white chalky material on epicardial surface of heart and serosal surface of liver, spleen, lung and enlargement of kidneys with necrotic foci were found (Fig. 1-A-D). Histopathologically, kidney sections revealed urate tophi that were having radiating fine needle shaped crystals (Fig. 2-A), associated with haemorrhages in some areas, dilated capillaries and congestion. In renal

parenchyma, granulomatous reaction was seen and the tubular epithelium had undergone varying degree of degeneration and mild, moderate to severe multifocal necrotic changes (Fig. 2-A and 2-B). De Galantha

staining revealed presence of urates in form of black crystals in the myocardium of heart and in tubular necrotic areas of kidneys either singly or in clumps.

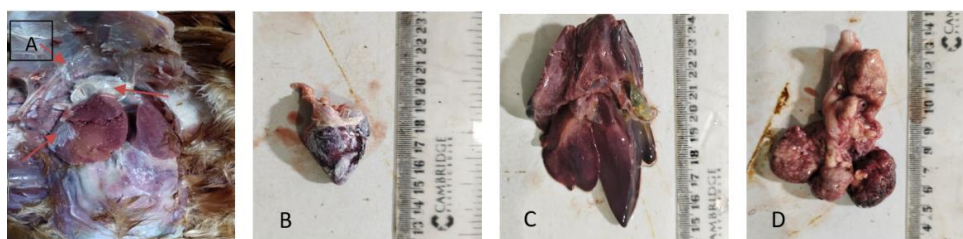


Fig. 1. A In-suit showing white chalky material of urate crystals in liver, heart. 1.B showing deposition of urate crystals on epicardial surface of heart. Showing deposition of urate crystals on serosal surface of liver (1.C) and Kidney (1.D)

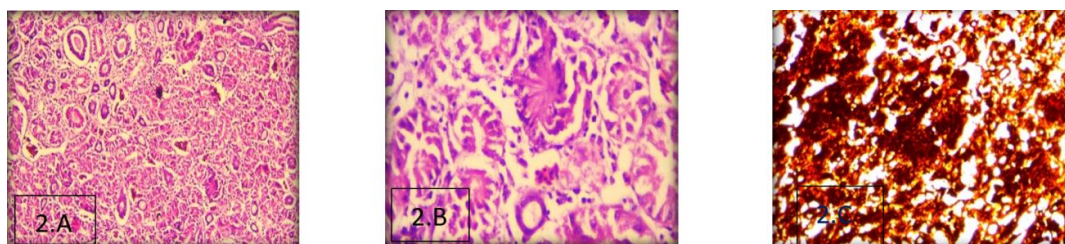


Fig. 2. A showing fine radiating crystals of urate deposition and tophi in tubules and renal parenchyma, HE X10. 1.B showing deposition of urate deposits in the form of tophi. HE x40. 1.C showing urate crystals in black cotton shape on de galanthas stain X 40.

DISCUSSION

Gout is a metabolic disorder resulting in hyperuricemia and the deposition of uric acid or urates in tissues of affected chickens. It showed that mortality was recorded in the month of July and August might due to the high humidity climate of Assam which favours the mycotoxin growth rapidly causes decrease in feed and water intake and the incidence mostly commonly occurred in Kampura, Dahlem red and Daothigir breeds in descending grades of breed order. The gross lesions like chalky white deposits on various visceral organs and histopathology of kidney shows the presence of multifocal urate tophi that were having radiating fine needle shaped crystals replacing the normal renal parenchyma with inflammatory reaction. On special staining with De Galantha revealed presence of urates crystals with black colour and background showing yellow colour.

CONCLUSIONS

The motality was recorded in the month of July and August might due to the high humidity climate of Assam and the incidence of mortality was recorded in Kampura, Dahlem red and Daothigir breeds in descending grades of breed order during the study.

Acknowledgement. The authors are grateful to the Head of the Department, Department of Veterinary Pathology, College

of Veterinary Science, Khanapara, AAU, Jorhat, for providing the essential facilities for the study.

Conflict of Interest. None.

REFERENCES

- Ali, R., Kamil, S. A., Amin, U., Mir, M. S., Shah, A., Kashani, B., Dar, T. A., Shah, S. A. and Qureshi, S. (2018). Clinicopathology of sodium bicarbonate induced gout in broiler chicken model. *Indian J. Vet. Pathol.*, 42(1), 58-63.
- Bulbule, N. R., Kapgata, S. S. and Chawak, M. M. (2014). Infectious causes of gout in chickens. *Adv Anim Vet Sci.*, 2(4), pp.255-260.
- De Galantha, E. (1935). De Galantha's Method for Demonstration of Urate Crystals. *Manual of Histological and Special Staining Techniques. Am. J. Clin. Pathol.*, 5, 165.
- Lakshmi Namratha, M., Kumar, Y.R. and Lakshman, M. (2019). Pathology of visceral gout in layer chicken. *Int. J. Recent Sci. Res.*, 10, 35546-35548.
- Luna, L. G. (1968). *Manual of Histologic staining methods of armed forces*, Institute of pathology, 3rd edition New York, Mc Graw Hill Book Company, New York, 220, 176-77 and 184-185.
- Mudasir, M., Dogra, S., Badroo, G. A., Nashirrudullah, N., Batoo, A. S., Javaid, M. and Bhat, M. A. (2017). Pathomorphological study of visceral gout in desi fowl. *Int. J. Curr. Microbiol. App. Sci.*, 6(10), 5039-5042.
- Sandhyarani, K., Madhuri, D. and Ravikumar, Y. (2021). Review-Gout in Chicken. *Adv. Anim. Vet. Sci.*, 10(3), 702-711.

How to cite this article: Udaya Sai Sitaram Tella, Mridusmrita Buragohain, Abhijit Deka, Sravan Kumar Reddy and M. Sai Kumar Reddy (2023). Occurrence and Pathology of Visceral Gout in Chickens. *Biological Forum – An International Journal*, 15(10): 1702-1703.